

CASE REPORTS

Drug induced chest pain—rare but important

Patrick Davey, David G Lalloo

Abstract

Pericarditis, usually viral in origin, is an infrequent cause of chest pain. Pericarditis due to drug allergy is even less frequent and is thus rarely considered in the differential diagnosis. A case is reported of a woman who presented with severe chest pain, caused by minocycline induced pericarditis. Such allergy may be more common than reported. It is suggested that drug induced pericarditis should be included in the differential diagnosis of acute chest pain.

(*Postgrad Med J* 2000;76:420-422)

Keywords: chest pain; pericarditis; minocycline; drug allergy

Chest pain is a frequent cause of acute hospital admission. Demographic factors, duration, exercise relation and site of the pain, associated symptoms, and the electrocardiogram (ECG) are all helpful in establishing the diagnosis. However it is often forgotten that adverse drug reactions can cause chest pain and a full drug history is vital. Here we present a case of pericardial pain due to an adverse reaction to an antibiotic taken for acne.

Case report

A 42 year old woman with longstanding acne was started on minocycline three weeks before presentation. After two weeks' treatment she developed low grade fever, cough, and dyspnoea. She was admitted to another hospital where no clear diagnosis was made. A chest x ray film at this time was normal. After two days' observation, during which she remained

afebrile, she was discharged home. Shortly thereafter she developed moderately severe anterior chest pain, related both to deep inspiration and to position, and her general practitioner arranged emergency admission. On examination she was in moderate discomfort, with no abnormal cardiovascular signs. No pericardial or pleural rub was heard. A chest x ray film and an isotope ventilation-perfusion scan were normal. Her ECG was very abnormal (fig 1), and the pattern of the abnormality was not typical for pericardial disease and raised the possibility that she might have a coronary or myocardial problem. Cardiac ultrasound showed vigorous left and right ventricular function, with normal myocardial density, and no evidence of pericardial disease. Cardiac enzymes (including creatine kinase) were not raised. A blood count showed marked eosinophilia, with an absolute eosinophil count of $13\,000 \times 10^9/l$. Though it was considered likely that minocycline had induced the eosinophilia which in turn had led to pericardial inflammation, the ECG was so worrying that it was felt appropriate to undertake coronary angiography. This revealed normal coronaries. Computed tomography of the thorax showed no evidence of pneumonitis. Once minocycline was discontinued her eosinophil count fell rapidly, her chest pain resolved, and at follow up six weeks later her ECG had returned to normal. The final diagnosis was minocycline induced eosinophilic pericarditis.

Discussion

This patient presented with pleuritic chest pain and a dramatically abnormal ECG, which

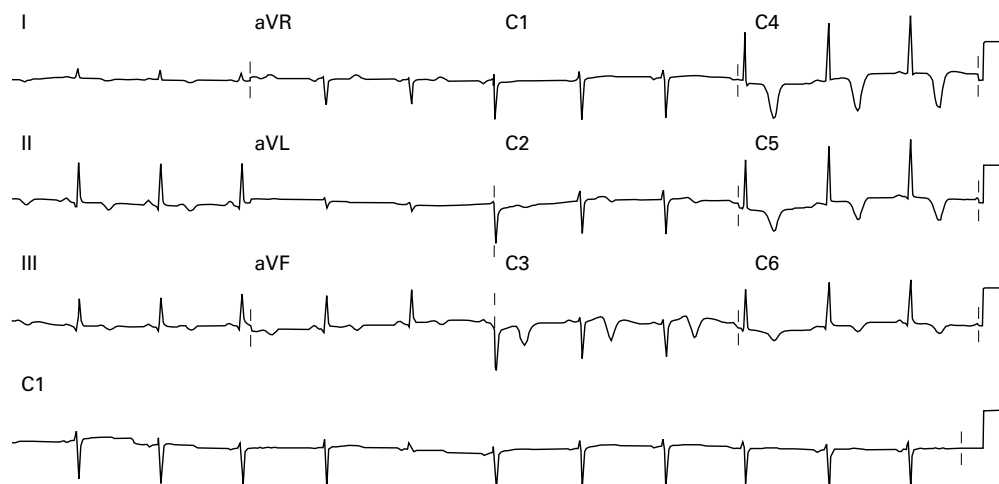


Figure 1 Admission ECG. There is widespread deep anterior T wave inversion suggestive of a lesion in the proximal portion of the left anterior descending coronary artery.

Nuffield Department
of Medicine, John
Radcliffe Hospital,
Oxford OX3 9DU, UK
P Davey
D G Lalloo

Correspondence to:
Dr Davey (e-mail:
patrick.davey@ndm.ox.ac.uk)

Submitted 12 March 1999
Accepted 16 December 1999

resolved on discontinuing minocycline. The chest pain was consistent with pericarditis, the ECG was typical for stage III of acute pericarditis (as classified by Braunwald), and the rapid return of the ECG back to normal as symptoms resolved likewise was consistent with pericarditis.¹ However this pattern of ECG abnormality can be associated with a myocardial or coronary problem and thus further investigations were carried out to exclude these other diagnosis. Active myocarditis was excluded by the absence of diagnostic features (such as a resting sinus tachycardia, heart failure, biochemical evidence of myocardial necrosis, or any ultrasound evidence of cardiac damage) and old myocarditis was excluded by the rapid return of the ECG to normal. The normal cardiac ultrasound examination excluded hypertrophic cardiomyopathy or other heart muscle disorder. Coronary disease was excluded by the normal coronary angiogram. We therefore concluded that her chest pains related to pericarditis, which, given the high eosinophil count could relate to an adverse drug reaction. This view was strengthened by the simultaneous improvement in her symptoms, in her ECG changes, and in the eosinophil count once minocycline was discontinued. It was felt unethical to rechallenge her with minocycline.

Thus this patient developed eosinophilia and pericardial pain as an adverse reaction to minocycline taken for acne. While it is well known that prolonged severe eosinophilia can lead to endomyocardial disease, particularly fibrosis of the ventricular apex or of the atrioventricular valvar apparatus, what is less well recognised is that acute hyper eosinophilia can also damage the heart and lead to myocardial disease, including conducting tissue damage or, as in this patient, pericardial disease.²⁻⁵ Eosinophil mediated pericardial diseases includes pericarditis, pericardial effusion which can be so large as to result in frank tamponade and, in the chronic phase, pericardial constriction.⁶⁻⁸ When eosinophilia is diagnosed it is always important to determine whether there is any underlying cause, such as a vasculitis (particularly Churg-Strauss syndrome or polyarteritis nodosum), asthma atopy, haematological malignancy, and, particularly in tropical countries, parasitosis.⁹⁻¹¹ In addition to these causes of eosinophilia adverse drug reactions should also be considered.⁴ Diagnosis of an adverse drug reaction depends partly on documenting symptomatic improvement on drug withdrawal, and, when felt to be ethically and medically appropriate, demonstrating relapse on rechallenge.¹² "In vitro" lymphocyte simulation tests have been proposed as a safe means of determining the presence of drug sensitivity but their accuracy remains to be established.^{13 14}

Many drugs have been reported as having the potential to induce pericarditis as an eosinophil mediated serositic adverse reaction and these include allergen immunotherapy, cephalosporin antibiotics, cromolyn sodium, and dantrolene.^{7 15-18} Furthermore many drugs have the potential to induce serositis, including pericarditis, in the absence of eosinophilia, sometimes through immune mechanisms, such

Learning points

- Pericarditis may be caused by drug reactions.
- ECG changes in drug induced pericarditis may be atypical and can mimic those found in coronary disease.
- Pericarditis due to adverse drug reactions may not be associated with eosinophilia.
- Drug induced pericarditis usually resolves on drug cessation.

as drug induced systemic lupus erythematosus or other vasculitis, sometimes because they are cytotoxic (for example azathioprine) and sometimes through unknown mechanisms, such as in the case of 5-aminosalicylic acid or the bisphosphonates.¹⁹⁻²⁴ Vaccines such as BCG and peptide drugs such as granulocyte macrophage colony stimulating factor can also rarely cause pericarditis.^{25 26}

Minocycline has been associated with a number of adverse reactions such as eosinophilic pneumonia and hepatitis, which may be life threatening, dermatitis, lymphadenopathy, neutropenia, and pseudotumour cerebri.^{18 27-31} There have to date, however, been no reports of minocycline toxicity resulting primarily in pericardial disease. Minocycline toxicity usually improves completely on drug withdrawal without other treatment being required. However corticosteroids may accelerate recovery from severe minocycline induced lung damage.^{14 32}

The mechanism of eosinophil mediated cardiac damage is not clear but is likely to be multifactorial. Eosinophils, through the release of proteins contained within their granules, particularly eosinophilic cationic protein and to a lesser extent major basic protein, can induce the release of histamine and tryptase from mast cells isolated from human hearts and thus induce cardiac damage.³³ Furthermore low concentrations of these granular proteins results in damage both to plasma membranes, possibly increasing permeability, and to at least two enzyme complexes (pyruvate dehydrogenase and 2-oxoglutarate dehydrogenase).^{34 35} Either directly or indirectly eosinophils may also stimulate the production of inflammatory mediator cytokines, such as interleukin-5.^{33 36 37} "In vitro" studies using eosinophils from patients with hypereosinophilic syndromes have shown that the supernatant obtained after overnight culture impairs myocardial contractile function, though this requires intact endothelium.³⁸ There are also isolated reports that cardiac damage results from eosinophil induced vasospasm.³⁹

Conclusion

We have presented a patient who developed eosinophilia and pericardial pain as an adverse reaction to minocycline taken for acne. Adverse drug reaction should always be considered in the differential diagnosis of pericardial pain.

- 1 Braunwald E. *Heart disease: a textbook of cardiovascular medicine*. 3rd Ed. Philadelphia: WB Saunders, 1988.
- 2 Andy JJ, Bishara FF, Soyinka OO. Relation of severe eosinophilia and microfilariasis to chronic African endomyocardial fibrosis. *Br Heart J* 1981;45:672-80.
- 3 Inoh T, Tsukitani M, Adachi Y, et al. A case of acute peri-myocarditis associated with delayed appearance of eosinophilia. *Kobe J Med Sci* 1980;26:223-8.
- 4 James TN, Kamb ML, Sandberg GA, et al. Postmortem studies of the heart in three fatal cases of the eosinophilia-myalgia syndrome. *Ann Intern Med* 1991;115:102-10.
- 5 Zientek DM, King, DL, Dewan SJ, et al. Hypereosinophilic syndrome with rapid progression of cardiac involvement and early echocardiographic abnormalities. *Am Heart J* 1995;130:1295-8.
- 6 Virmani R, Chun, PK, Dunn BE, et al. Eosinophilic constrictive pericarditis. *Am Heart J* 1984;107:803-7.
- 7 Slater EE. Cardiac tamponade and peripheral eosinophilia in a patient receiving cromolyn sodium. *Chest* 1978;73:878-9.
- 8 Herry I, Philippe B, Hennequin C, et al. Acute life-threatening toxocaral tamponade. *Chest* 1997;112:1692-3.
- 9 Rashwan MA, Ayman, M, Ashour S, et al. Endomyocardial fibrosis in Egypt: an illustrated review (see comments). *Br Heart J* 1995;73:284-9.
- 10 Punyagupta S, Juttijudata P, Bunnag T. Eosinophilic meningitis in Thailand. Clinical studies of 484 typical cases probably caused by *Angiostrongylus cantonensis*. *Am J Trop Med Hyg* 1975;24:921-31.
- 11 Van den Bosch JM, Wagenaar SS, Westermann CJ. Asthma, eosinophilic pleuropneumonia, and pericarditis without vasculitis. *Thorax* 1986;41:571-2.
- 12 Yokoyama A, Mizushima Y, Suzuki H, et al. Acute eosinophilic pneumonia induced by minocycline: prominent Kerley B lines as a feature of positive re-challenge test. *Jpn J Med* 1990;29:195-8.
- 13 Sakano T, Takahashi H, Mori M, et al. Eosinophilic peritonitis and drug-induced lymphocyte transformation in vitro. *Perit Dial Int* 1995;15:76-7.
- 14 Bando T, Fujimura M, Noda Y, et al. Minocycline-induced pneumonitis with bilateral hilar lymphadenopathy and pleural effusion. *Intern Med* 1994;33:177-9.
- 15 Quirce S, Fernandez Rivas M, Losada E, et al. Recurrent pericarditis: a rare complication of allergen immunotherapy. *Allergy* 1992;47:343-5.
- 16 Felman RH, Sutherland DB, Conklin JL, et al. Eosinophilic cholecystitis, appendiceal inflammation, pericarditis, and cephalosporin-associated eosinophilia. *Dig Dis Sci* 1994;39:418-22.
- 17 Miller DH, Haas LF. Pneumonitis, pleural effusion and pericarditis following treatment with dantrolene. *J Neurol Neurosurg Psychiatry* 1984;47:553-4.
- 18 Bentur L, Bar-Kana Y, Livni E, et al. Severe minocycline-induced eosinophilic pneumonia: extrapulmonary manifestations and the use of in vitro immunoassays. *Ann Pharmacother* 1997;31:733-5.
- 19 Mullick FG, McAllister HA Jr, Wagner BM, et al. Drug related vasculitis. Clinicopathologic correlations in 30 patients. *Hum Pathol* 1979;10:313-25.
- 20 Carey RM, Coleman, M, Feder A. Pericardial tamponade: a major presenting manifestation of hydralazine-induced lupus syndrome. *Am J Med* 1973;54:84-7.
- 21 Simpson CD. Azathioprine-induced pericarditis in a patient with ulcerative colitis. *Can J Gastroenterol* 1997;11:217-19.
- 22 Gujral N, Friedenber F, Friedenber J, et al. Pleuropericarditis related to the use of mesalamine. *Dig Dis Sci* 1996;41:624-6.
- 23 Iaquinto G, Sorrentini I, Petillo FE, et al. Pleuropericarditis in a patient with ulcerative colitis in longstanding 5-aminosalicylic acid therapy. *Ital J Gastroenterol* 1994;26:145-7.
- 24 Adami S, Zamberlan N. Adverse effects of bisphosphonates. A comparative review. *Drug Safety* 1996;14:158-70.
- 25 Lyons D, Miller I, Jeffers A. Systemic hypersensitivity reaction to intravesical BCG. *Scott Med J* 1994;39:49-50.
- 26 Stern AC, Jones TC. The side-effect profile of GM-CSF. *Infection* 1992;20(suppl 2):S124-7.
- 27 Dykhuizen RS, Zaidi AM, Godden DJ, et al. Minocycline and pulmonary eosinophilia. *BMJ* 1995;310:1520-1.
- 28 MacNeil M, Haase DA, Tremaine R, et al. Fever, lymphadenopathy, eosinophilia, lymphocytosis, hepatitis, and dermatitis: a severe adverse reaction to minocycline. *J Am Acad Dermatol* 1997;36:347-50.
- 29 Kaufmann D, Pichler W, Beer JH. Severe episode of high fever with rash, lymphadenopathy, neutropenia, and eosinophilia after minocycline therapy for acne. *Arch Intern Med* 1994;154:1983-4.
- 30 Otero M, Goodpasture HC. Pulmonary infiltrates and eosinophilia from minocycline (letter). *JAMA* 1983;250:2602.
- 31 Min DI, Burke PA, Lewis WD, et al. Acute hepatic failure associated with oral minocycline: a case report. *Pharmacotherapy* 1992;12: 68-71.
- 32 Sitbon O, Bidel N, Dussot C, et al. Minocycline pneumonitis and eosinophilia. A report on eight patients. *Arch Intern Med* 1994;154:1633-40.
- 33 Patella V, de Crescenzo G, Marino I, et al. Eosinophil granule proteins are selective activators of human heart mast cells. *Int Arch Allergy Immunol* 1997;113:200-2.
- 34 Spry CJ, Tai PC, Davies J. The cardiotoxicity of eosinophils. *Postgrad Med J* 1983;59:147-53.
- 35 Tai PC, Hayes, DJ, Clark JB, et al. Toxic effects of human eosinophil products on isolated rat heart cells in vitro. *Biochem J* 1982;204:75-80.
- 36 Patella V, de Crescenzo G, Marino I, et al. Eosinophil granule proteins activate human heart mast cells. *J Immunol* 1996;157:1219-25.
- 37 Desreumaux P, Janin A, Dubucquoi S, et al. Synthesis of interleukin-5 by activated eosinophils in patients with eosinophilic heart diseases. *Blood* 1993;82:1553-60.
- 38 Shah AM, Brutsaert DL, Meulemans AL, et al. Eosinophils from hyper eosinophilic patients damage endocardium of isolated feline heart muscle preparations. *Circulation* 1990;81:1081-8.
- 39 Takahashi N, Kondo K, Aoyagi J. Acute myocardial infarction associated with hyper eosinophilic syndrome in a young man. *Jpn Circ J* 1997;61:803-6.

Milk alkali syndrome—an unusual syndrome causing an unusual complication

S George, J D A Clark

Abstract

Milk alkali syndrome is rare and although pancreatitis secondary to hypercalcaemia is well recognised, there has only been one other reported case of pancreatitis secondary to the milk alkali syndrome. Such a case, caused by self medication of over the counter medication, is reported.

(*Postgrad Med J* 2000;76:422-423)

Keywords: milk alkali syndrome; pancreatitis; over the counter medication

Case report

A 44 year old women presented as an emergency with a two day history of generalised abdominal pain and vomiting. She had a history of renal calculi which had been removed some years previously. Subsequent radiology at the time showed delayed renal excretion of contrast by the right kidney, although serum urea and

electrolytes were normal. She took no regular prescribed medication. Direct questioning revealed that she suffered from dyspepsia.

Examination showed an overweight woman who was drowsy, clinically dehydrated, and tachycardic with a heart rate of 110 beats/min. She was afebrile. Blood pressure was 160/110 mm Hg. On abdominal examination there was generalised tenderness but without signs of peritonism. Serum electrolytes, other biochemistry, and haematological values on admission are shown in table 1. Of note is the corrected serum calcium at 4.0 mmol/l.

A diagnosis of acute pancreatitis was made and she was admitted to the intensive care unit where she required low calcium total parenteral nutrition. A normal liver and gall bladder were seen on abdominal ultrasound. Both kidneys showed a degree of hydronephrosis. The serum calcium normalised within three days.

Addenbrookes
Hospital NHS Trust,
Cambridge, UK
S George

West Suffolk Hospital
NHS Trust, Hardwick
Lane, Bury St
Edmunds IP33 2QZ,
UK
J D A Clark

Correspondence to:
Dr Clark
(e-mail: John.Clark@
wsh-tr.anglox.nhs.uk)

Submitted 22 June 1999
Accepted 16 November 1999

Table 1 Biochemical and haematological values on admission (normal range)

| | |
|--|---|
| Sodium 136 mmol/l (136–146) | Potassium 3.8 mmol/l (3.5–5.1) |
| Urea 11.4 mmol/l (2.5–6.7) | Creatinine 216 µmol/l (<120) |
| Glucose 7.1 mmol/l (3–6) | Total protein 80 g/l (60–80) |
| Albumin 46 g/l (36–58) | Bilirubin 17 µmol/l (<17) |
| Alanine aminotransferase 15 IU/l (<25) | Amylase 3500 U/l (<220) |
| Alkaline phosphatase 163 IU/l (30–120) | Corrected calcium 4.0 mmol/l (2.2–2.7) |
| Phosphate 1.10 mmol/l (0.8–1.4) | Total white cell count 23.5×10 ⁹ /l (4–11) |
| Haemoglobin 150 g/l (115–165) | Platelets 348×10 ⁹ /l (150–400) |

Intravenous urography performed two days after transfer to a general ward showed no ureteric stones. An ultrasound of the thyroid and parathyroid glands showed a multinodular goitre but no parathyroid masses. Intact parathyroid hormone measured while she was still hypercalcaemic was 8 ng/l (normal range 9–54) suggesting a non-parathyroid cause of the hypercalcaemia. Serum angiotensin converting enzyme was within normal limits at 36 IU/l (15–70) making sarcoidosis unlikely.

Further questioning revealed that the patient had been taking large amounts of “over the counter” calcium containing antacids. For the past two to three years she had been taking up to 70 “Rennies” tablets (Roche Consumer Health, Welwyn Garden City) per week. Each tablet contains 680 mg of calcium carbonate, averaging about 4.5 g of calcium carbonate per day. Barium swallow showed reflux disease with no ulceration.

She was discharged on lansoprazole 20 mg daily and on follow up was asymptomatic with normal electrolytes and a serum calcium within normal limits.

Discussion

Milk alkali syndrome was first described by Sippy in 1915 as the triad of hypercalcaemia, alkalosis, and renal impairment.¹

There have been many cases of pancreatitis secondary to hypercalcaemia, but we have only found one other case in the literature when pancreatitis has been due to milk alkali syndrome.²

This case fulfils all the criteria for the milk alkali syndrome and in the absence of any other identifiable causes, the pancreatitis can be attributed to it. In the only other reported case of pancreatitis secondary to milk alkali syndrome, the patient had also been self medicating with up to 3 g of calcium daily in an attempt to treat dyspepsia.

Learning points

- Milk alkali syndrome is likely to become more common in the light of increased self medication by patients who fear osteoporosis.
- It can result in life threatening complications such as pancreatitis.
- It is diagnosed only after taking a careful history including details of all self medication.

Certain metabolic factors can increase susceptibility to the milk alkali syndrome. Our patient may have been at an increased risk of the milk alkali syndrome because of her prior renal pathology resulting in tubular dysfunction, thus making her more susceptible to alkalosis and hypercalcaemia.³

In the post H₂-blocker era this syndrome had been becoming increasingly rare. However, over the counter medicines are generally thought to be safe by the public and in the wake of the fear of osteoporosis an increase in consumption of calcium carbonate containing dietary supplements may perhaps reverse this trend. In fact, Beall reported seven cases of milk alkali syndrome who were seen between 1990–93 accounting for 12% of cases presenting to their hospital with severe hypercalcaemia.⁴

It can cause life threatening complications and indeed both our patient and the one described by Brandwein and Sigman² needed admission to an intensive care unit. It is a diagnosis that is not easily made unless a careful patient history is taken which should include details of all self medication.

1 Sippy BW. Gastric and duodenal ulcer. Medical cure by and efficient removal of gastric juice corrosion. *JAMA* 1915;64:1625–30.

2 Brandwein SL, Sigman KM. Milk-alkali syndrome and pancreatitis. *Am J Med Sci* 1994;308:173–6.

3 Peraino RA, Suki WN. Urine HCO₃ augments renal calcium absorption independent of systemic acid-base changes. *Am J Physiol* 1980;238:F394–8.

4 Beall DP, Scofield RH. Milk-alkali syndrome associated with calcium carbonate consumption. *Medicine* 1995;74:89–96.

Primary hypothyroidism masquerading as hepatic encephalopathy: case report and review of the literature

Nicole Thobe, Pamela Pilger, Michael P Jones

Abstract

A 74 year old woman with hepatitis C of long duration was admitted to hospital in hyperammonaemic coma. Despite aggressive treatment of hepatic encephalopathy, there was no clinical improvement. As part of her evaluation for other causes of altered mental status, she was found to be profoundly hypothyroid. Treatment with thyroid replacement hormone was accompanied by prompt normalisation of her mental status and hyperammonaemia. Hypothyroidism may exacerbate hyperammonaemia and portosystemic encephalopathy in patients with otherwise well compensated liver disease. Hypothyroidism should be considered in the differential diagnosis of encephalopathy in patients with liver disease.

(*Postgrad Med J* 2000;76:424–426)

Keywords: hypothyroidism; cirrhosis; hyperammonaemia; coma

Although the liver is considered to be a hormone independent organ, it is hormone responsive and endocrine alterations affect hepatic function. We present a case of metabolic coma due to hyperammonaemia and myxoedema in a patient with well compensated cirrhosis and primary hypothyroidism. Coma developed after discontinuation of thyroid hormone replacement and it appears that hypothyroidism precipitated hyperammonaemia.

Case report

A previously healthy, functional 74 year old woman was admitted in coma after being found unresponsive in her flat. Several days before she had fallen and struck her head without loss of consciousness. Since then, she had exhibited slurred speech and did not seem herself. Her past medical history as reported at the time of admission was remarkable for well compensated hepatitis C of approximately 20 years' duration. A search of the patient's flat found no prescription medication. She neither smoked nor drank.

Examination revealed a thin female in coma with shallow, irregular respirations. Her pulse was 95 beats/min, blood pressure was 120/50 mm Hg, and respirations were 6–8/min. A healing contusion was noted on her forehead. Examination of the abdomen showed the liver to be of normal span with a firm edge. There was no splenomegaly or ascites noted. There

was no oedema or spider angiomas, but palmar erythema was noted. Neurologically, she was unresponsive. Her Glasgow coma score was 3.

A complete blood count, electrolytes, urinalysis, and prothrombin time were within normal limits. Results of liver chemistry were (normal limits): aspartate aminotransferase (AST) 156 U/L (11–35), alanine aminotransferase (ALT) 53 U/L (7–46), alkaline phosphatase 113 U/L (46–139), total bilirubin 37.6 $\mu\text{mol/l}$ (3.4–20.5), direct bilirubin 10.3 $\mu\text{mol/l}$ (0–5.1), and albumin 34 g/l (34–48). The serum ammonia concentration was 124 $\mu\text{mol/l}$ (10–47). Computed tomography of the head revealed no evidence of intracranial haemorrhage or cerebrovascular accident. Lumbar puncture revealed a normal opening pressure, no gross or microscopic blood, and normal concentrations of glucose and protein. An echocardiogram showed no valvular abnormalities, pericardial effusion, thrombus, or vegetations. Ultrasound examination of the abdomen disclosed a small, echogenic liver and splenomegaly. An electroencephalogram revealed severe generalised slowing with triphasic waves.

A diagnosis of hepatic coma was made and the patient started on lactulose. Within 24 hours, the ammonia level decreased to 52 $\mu\text{mol/l}$, but her mental status was unchanged. Because of the poor clinical response, other aetiologies for metabolic encephalopathy were sought. A morning cortisol was normal and a serum toxin screen was negative. Her serum thyroid stimulating hormone was 104 mU/l (0.47–6.90).

Intravenous levothyroxine 0.05 mg was administered intravenously every six hours. Over the next day, the patient gradually regained consciousness and her mental status returned to normal over the following days. Once alert, she informed the staff that she had a long history of hypothyroidism treated with levothyroxine. She had discontinued it two months before admission at the urging of her chiropractor who had instead recommended a herbal preparation to stimulate the thyroid. She was discharged to home shortly thereafter on levothyroxine and is euthyroid with no evidence of hepatic dysfunction.

Discussion

This unusual case demonstrates the complex interactions of liver and thyroid. It shows that hyperammonaemia may accompany profound hypothyroidism in patients with coexisting liver disease and that the presence of

University of
Cincinnati, Cincinnati,
Ohio, USA:
Department of
Internal Medicine
N Thobe
P Pilger

Division of Digestive
Diseases
M P Jones

Correspondence to:
Dr Michael P Jones,
Northwestern University
School of Medicine, 251 East
Huron Street, Galter Pavilion
4–104, Chicago, IL
60611–2908, USA (e-mail:
mpjones@nmh.org)

Submitted 30 July 1999
Accepted 22 November 1999

hyperammonaemia, particularly in the absence of other evidence of hepatic decompensation, should prompt a search for hypothyroidism.

Thyroid test abnormalities are common in both acute and chronic liver disease, but most patients remain euthyroid. The most common abnormalities are increases of total thyroxine and thyroxine binding globulin in association with normal free thyroxine and thyroid stimulating hormone concentrations.^{1,2} Increased concentrations of total thyroxine appear due to increased thyroxine binding globulin, which have been variously attributed to release by damaged hepatocytes, decreased thyroxine binding globulin catabolism, or increased synthesis by regenerating hepatocytes.³ Serum triiodothyronine concentrations in chronic liver disease are variable but generally decrease with increasing hepatic dysfunction.⁴

Thyroid dysfunction may also occur in association with chronic liver disease most commonly in immune mediated liver disorders, particularly autoimmune chronic active hepatitis, primary biliary cirrhosis, and hepatitis C.^{5,6} Hypothyroidism is more common than hyperthyroidism. Antithyroglobulin and antimicrosomal antibodies are often positive even in the absence of thyroid dysfunction. Thyroid antibodies are detected in 36%–72% of patients with autoimmune chronic active hepatitis and primary biliary cirrhosis and in 6%–14% of patients with chronic hepatitis C.^{6,7}

Conversely, both hyperthyroidism and hypothyroidism can adversely affect hepatic structure and function. Hyperthyroidism is associated with increases in serum transaminases, alkaline phosphatase, and serum bilirubin concentrations.⁸ Liver biopsy specimens in hyperthyroid patients most often show non specific changes including hepatocyte degeneration, cholestasis, and Kupffer cell hyperplasia.⁸ Although hyperthyroidism may alter hepatic histology and biochemistry, the clinical picture is usually dominated by the signs and symptoms of hyperthyroidism and diagnosis is not difficult.

Differentiation of hypothyroidism from hepatic dysfunction can be difficult, particularly in patients with coexisting liver disease as symptoms of hypothyroidism and chronic liver disease are similar. In both, patients may present with fatigue or mental status changes, as well as weakness, myalgias, and dyspnoea on exertion. Oedema, ascites, and pleural effusion are seen in both disorders. Transaminase increases are common, often with AST raised out of proportion to ALT, as was seen here. While these increases may be caused by the steatosis which has been reported in hypothyroidism, AST increases may also be caused by myopathy.

While myxoedema may cause coma, it may not have been the sole cause of coma in this patient. Profound hyperammonaemia was noted at the time of admission without other evidence for hepatic dysfunction, such as coagulopathy, jaundice, or ascites. The effect of

Learning points

- Thyroid and liver disease may coexist.
- Differentiation of hyperthyroidism from chronic liver disease may occasionally be difficult.
- Hyperammonaemia may be precipitated by hyperthyroidism in patients with liver disease.
- Altered mental status and hyperammonaemia in patients with coexisting liver disease may be caused by hyperthyroidism in the absence of primary hepatic decompensation.

thyroxine on ammonia metabolism is not well understood. Although protein synthesis is decreased in hypothyroidism,⁹ urea production and the activities of urea cycle enzymes are increased in rats with experimental hypothyroidism.^{10,11} These observations would suggest that hypothyroidism may increase ammonia production. There is only one other reported case of hypothyroidism, hyperammonaemia, and apparent portosystemic encephalopathy in a patient in a patient with cirrhosis.¹² In that report, a patient with altered mental status and decompensated liver disease, including hyperammonaemia, failed to respond to protein restriction and lactulose. Further investigation disclosed hypothalamic hypothyroidism and the patient's mental status was restored after administration of thyroxine. Interestingly, the electroencephalograms in both this and the previous reports disclosed generalised slowing and triphasic waves suggestive of hepatic encephalopathy. While this pattern is seen in a variety of metabolic encephalopathies, including hyperthyroidism, it is uncommon in hypothyroidism which more often demonstrates only diffuse slowing.¹³

In summary, differentiating hypothyroidism from hepatic dysfunction may occasionally be difficult, particularly in the setting of pre-existing liver disease. Hyperammonaemia and mental status changes in chronic liver disease may be due to hypothyroidism. If suspected portosystemic encephalopathy does not respond to therapy, clinicians should evaluate for coexistent hypothyroidism.

1 L'Age M, Meinhold H, Wenzel KW, *et al.* Relations between serum levels of TSH, TBG, T₄, T₃, and various histologically classified chronic liver diseases. *J Endocrinol Invest* 1980;4:379–83.

2 Borzio M, Caldara R, Borzio F, *et al.* Thyroid function tests in chronic liver disease: evidence for multiple abnormalities despite clinical euthyroidism. *Gut* 1983;24:631–6.

3 Huang MJ, Liaw YF. Clinical associations between thyroid and liver diseases. *J Gastroenterol Hepatol* 1995;10:344–50.

4 Hepner GW, Chopra IJ. Serum thyroid hormone levels in patients with liver disease. *Arch Intern Med* 1979;139:1117–20.

5 Crowe JP, Christensen E, Butler J, *et al.* Primary biliary cirrhosis: the prevalence of hypothyroidism and its relationship to thyroid autoantibodies and sicca syndrome. *Gastroenterology* 1980;78:1437–41.

6 Tran A, Quaranta JF, Benzaken S, *et al.* High prevalence of thyroid autoantibodies in a prospective series of patients with chronic hepatitis C before interferon therapy. *Hepatology* 1993;17:417–19.

7 Huang MJ, Wu SS, Liaw YF. Thyroid abnormalities in patients with chronic viral hepatitis. *Hepatology* 1994;20:1651–2.

- 8 Huang MJ, Li KL, Wei JS, et al. Sequential liver and bone biochemical changes in hyperthyroidism: revisited by a prospective controlled follow-up study. *Am J Gastroenterol* 1994;89:1071-6.
- 9 Ingbar SH. Effects of thyroid hormones on metabolic processes. In: Wilson JD, Foster DW, eds. *Williams textbook of endocrinology*. 7th Ed. Philadelphia: WB Saunders, 1985: 738.
- 10 Marti J, Portles M, Jimenez-Nacher I, et al. Effect of thyroid hormone on urea biosynthesis and related processes in rat liver. *Endocrinology* 1988;123:2167-74.
- 11 Cheema-Dhadli S, Jungas RL, Halperin ML. Regulation of urea synthesis by acid-base balance in vivo: role of NH₃ concentration. *Am J Physiol* 1987;252:F221-5.
- 12 Hitoshi S, Terao Y, Sakuta M. Portal-systemic encephalopathy and hypothalamic hypothyroidism: the effect of thyroid hormone on ammonia metabolism. *Intern Med* 1993;32: 655-8.
- 13 Markland ON. EEG in diffuse encephalopathies. *J Clin Neurophysiol* 1984;4:361-9.

Turkish pepper (extra hot)

Alexander Woywodt, Alena Herrmann, Mira Choi, Ursula Goebel, Friedrich C Luft

Abstract

A 38 year old female office worker was admitted with a newly discovered blood pressure of 250/110 mm Hg. Evaluation for secondary forms of hypertension was negative and treatment was begun. Sodium excretion was markedly reduced, plasma aldosterone was normal, and plasma renin activity was low. Therefore, presence of an aldosterone-like activity was suspected. Eventually, the patient confessed to abusing "Turkish Pepper", a brand of Scandinavian liquorice candies and "Fisherman's Friend", another brand of liquorice candies, concurrently. After eliminating liquorice from her diet, the hypertension disappeared thus allowing her antihypertensive treatment to be stopped.

(*Postgrad Med J* 2000;76:426-428)

Keywords: liquorice; hypertension

Hypertension is among the most frequently encountered medical problems. Having excluded secondary forms of hypertension such as renal artery stenosis, hyperthyroidism, pheochromocytoma, mineralocorticoid and cortisol excess, clinicians commonly assign their patients the label of "essential" hypertension. Dietary causes of hypertension such as excessive liquorice consumption are often overlooked. Clinicians often fail to ask about liquorice ingestion and patients are unaware of liquorice as a potential health hazard. We present a case of liquorice "abuse", a common form of hypertension in industrialised countries, and provide a brief review of the disorder.

Case report

A 38 year old office worker presented with worsening headache and decreased appetite. She had suffered from migraine for years. The remainder of her previous medical history was unremarkable. She received no regular medication except for an oral contraceptive preparation. On admission, she appeared distressed but not acutely ill. Her blood pressure was 230/130 mm Hg and a trace of pitting pedal oedema was present. Grade 1 hypertensive retinopathy was noted. The remainder of the physical examination was unremarkable.

Serum creatinine, urine analysis, arterial blood gas values, and thyroid hormones were normal. Her serum potassium concentration was 3.9 mmol/l. Urinary catecholamines and plasma cortisol were normal. Electrocardiography, chest radiography, and a duplex scan of the renal arteries were normal. Urine sodium excretion was reduced to 17 mmol/day. Urinary cortisol was 196 nmol/24 hour (high normal), urinary aldosterone was 1.3 nmol/24 hour (low), and plasma renin activity was 0.15 ng/l (very low) suggesting presence of an aldosterone-like substance.

Further inquiries revealed daily consumption of large amounts of "Turkish Pepper" (Karl Fazer Ltd, Helsinki, Finland, fig 1), a brand of liquorice candies containing 200 mg glycyrrhizic acid and 1.5 g of sodium/100 g. Moreover, to our astonishment, the patient was incidentally seen ingesting "Fisherman's Friend" (Lofthouse Ltd, Fleetwood, UK, fig 2) liquorice lozenges containing 200 mg glycyrrhizic acid and 60 mg sodium chloride/100 g.



Figure 1 "Turkish Pepper": a strong brand of liquorice candies manufactured in Finland.

Department of
Nephrology,
Franz-Volhard-Clinic,
Charité Campus
Berlin-Buch,
Humboldt-University,
Berlin, Germany

A Woywodt
A Herrmann
M Choi
U Goebel
F C Luft

Correspondence to:
Dr A Woywodt, Department
of Nephrology, University of
Hannover School of
Medicine,
Carl-Neuberg-Strasse-1,
30625 Hannover, Germany
(e-mail: woywodt@aol.com)

Submitted 26 April 1999
Accepted 26 April 1999



Figure 2 "Fisherman's Friend": a popular brand of strong liquorice candies manufactured in the UK.

Box 1: Inhibitors of 11 β -HSD capable of inducing hypertension

- Confectionery: liquorice sticks, bricks, cakes, toffee, bars, balls, tubes, Catherine wheels, pastilles
- Chewing gum (Stimorol)
- Liquorice flavoured cough mixtures and teas
- Herbal cough mixtures
- Liquorice tea
- Liquorice root
- Chewing tobacco
- Belgian beers
- Alcoholic beverages: pastis, raki, ouzo, Pernod

She also reported ingestion of increasing amounts of the lozenges before admission.

Blood pressure control was first achieved with intravenous urapidil; subsequently, metoprolol was begun. Later, ramipril and hydrochlorothiazide were added. However, while receiving a strictly liquorice-free diet, the patient became hypotensive. Ramipril and hydrochlorothiazide were discontinued and she was discharged with metoprolol as a maintenance treatment for migraine.

Discussion

Liquorice is manufactured from the root of *Glycyrrhiza glabra*, a Mediterranean shrub from the family papilionaceae. Its medicinal use has been advocated since antiquity. The Greek physician Dioskorides reported its use in wound treatment and a liquorice root was reportedly found in the vicinity of Tutankhamun's grave in Egypt. In the 14th century, Conrad of Meganberg in Germany mentioned liquorice called "bear's droppings". Even the French emperor Napoleon was reportedly a notorious liquorice addict.

Hypertension due to liquorice was first recognised in the 1950s in the Netherlands where liquorice is extremely popular. Initially, a direct mineralocorticoid effect was proposed.¹ Forty years later, research into steroid metabolism led to an understanding of the disorder. For years, specificity of mineralocorticoid action had been believed to be receptor mediated. However, more recent research showed that both cortisol and mineralocorticoid

Learning points

- Both cortisol and aldosterone bind the mineralocorticoid receptor. In target tissues for mineralocorticoid action, specificity of aldosterone action in the presence of cortisol is mediated by 11 β -HSD which converts cortisol into cortisone. The latter is incapable of binding the mineralocorticoid receptor.
- Inherited defects of 11 β -HSD are responsible for endogenous renal cortisol excess associated with the syndrome of AME, a rare form of hypertension in children. Glycyrrhetic acid, the metabolite of glycyrrhizic acid in liquorice, is a potent inhibitor of 11 β -HSD and liquorice induced hypertension closely resembles AME from a pathogenetic point of view.
- In hypertensive patients, particularly in young women employed in office jobs and in patients who have recently stopped smoking, inquiring into dietary habits is mandatory in order to identify ingestion of 11 β -hydroxysteroid dehydrogenase inhibitors such as liquorice.

hormones are capable of binding the mineralocorticoid receptor. These findings led to the discovery of 11 β -hydroxysteroid dehydrogenase (11 β -HSD),² an enzyme that oxidises cortisol into cortisone, the 11-keto form that is incapable of binding to the mineralocorticoid receptor. Therefore, specificity of mineralocorticoid action is enzyme, not receptor, mediated.³ In mineralocorticoid sensitive tissues, such as the distal tubule, 11 β -HSD prevents excess cortisol from binding to the mineralocorticoid receptor thus allowing for aldosterone action.⁴ Subsequently, a genetic defect in 11 β -HSD was found to be the cause of the syndrome of apparent mineralocorticoid excess (AME), a rare form of hypertension in children clinically resembling hyperaldosteronism except for the fact that plasma aldosterone is undetectable. Endogenous cortisol, which binds to the renal mineralocorticoid receptor because of absent 11 β -HSD is the salient feature of AME.⁵ Subsequently, remarkable similarities between AME and liquorice induced hypertension were appreciated, leading to the discovery that glycyrrhetic acid, a metabolite of glycyrrhizic acid in liquorice, is a potent inhibitor of 11 β -HSD.⁶ The time course of liquorice ingestion, suppression of the renin-aldosterone axis, and increased urinary excretion of cortisol metabolites has been demonstrated in healthy volunteers.⁷

A broad variety of confectionery and beverages contain glycyrrhizic acid (box 1). However, severe hypertension is almost exclusively due to heavy consumption of strong liquorice candies whereas ingestion of moderate amounts is quite safe. A study in Iceland demonstrated that regular consumption of small amounts of liquorice suffices to induce hypertension in volunteers.⁸ Our patient concomitantly ingested two brands of liquorice candies containing large amounts of glycyrrhizic acid

and sodium chloride. Her urinary sodium excretion was markedly reduced suggesting that (provided that urine collection was adequate) she was not in equilibrium which would eventually have led to normal urinary sodium excretion. Therefore, although we cannot strictly prove a cause-and-effect relationship, we assume that her hypertension was caused by recent large amounts of liquorice.

Women receiving oral contraceptives are predominantly affected and a large proportion of patients is employed in office jobs. Individual susceptibility may play a part as many normotensive women report abuse of liquorice. An occasional patient may be a smoker who recently stopped only to "abuse" liquorice as a substitute. Near fatal cases have been reported⁹ and severe neurological rhabdomyolysis may occur when profound hypokalaemia is present.¹⁰

Hypertension is among the most frequently encountered problems in general internal medicine. Inquiring into liquorice habits must be part of the initial assessment to allow for a timely diagnosis of this common and easily treatable form of hypertension.

Mrs Pia Virtanen (Fazer Ltd, Helsinki, Finland), and Mr Dennis Walker (Lofthouse of Fleetwood, Fleetwood, UK) very kindly provided information regarding the ingredients of their

respective products. In particular, we are indebted to Mrs Ilse Böger (Kadó liquorice store, Berlin) who introduced us to the art and science of liquorice confectionery.

This paper is dedicated to Professor K Sack, Consultant Emeritus, Department of Medicine/Nephrology, University of Lübeck Medical School, Lübeck, Germany.

- 1 Molhuysen JA, Gerbrandy J, de Vries LA, et al. A liquorice extract with deoxycortone-like action. *Lancet* 1950;ii:381-6.
- 2 Funder JW, Pearce PT, Smith R, et al. Mineralocorticoid action. Target tissue specificity is enzyme, not receptor, mediated. *Science* 1988;242:583-5.
- 3 Oppermann UCT, Persson B, Jörnvall H. The 11 β -hydroxysteroid dehydrogenase system, a determinant of glucocorticoid and mineralocorticoid action—function, gene organization and protein structures of 11 β -hydroxysteroid dehydrogenase isoforms. *Eur J Biochem* 1997;249:355-60.
- 4 Seckl JR, Brown RW. 11-beta-hydroxysteroid dehydrogenase: on several roads to hypertension. *J Hypertens* 1994;12:105-12.
- 5 Stewart PM, Corrie JET, Shackleton CHL, et al. Syndrome of apparent mineralocorticoid excess: a defect in the cortisol-cortisone shuttle. *J Clin Invest* 1988;82:340-9.
- 6 Stewart PM, Wallace AM, Valentino R, et al. Mineralocorticoid activity of liquorice: 11-beta-hydroxysteroid dehydrogenase activity comes of age. *Lancet* 1987;ii:821-4.
- 7 Farese RV, Biglieri EG, Shackleton CHL, et al. Licorice-induced hypermineralocorticoidism. *N Engl J Med* 1991;325:1223-7.
- 8 Sigurjonsdottir HA, Ragnarsson J, Franzson L, et al. Is blood pressure commonly raised by moderate consumption of liquorice? *J Hum Hypertens* 1995;9:345-8.
- 9 Chamberlain JJ, Abolnik IZ. Pulmonary edema following a licorice binge. *West J Med* 1997;167:184.
- 10 Barrella M, Lauria G, Quatralo R, et al. Hypokaliemic rhabdomyolysis associated with liquorice ingestion: report of an atypical case. *Ital J Neurol Sci* 1997;18:217-20.