

Case report

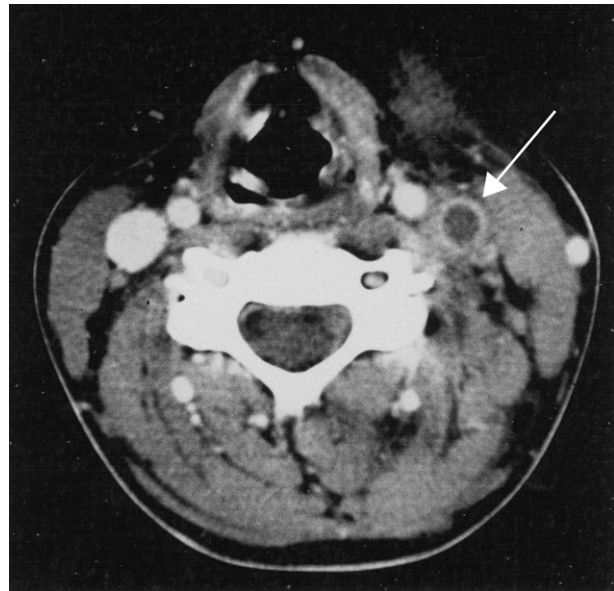
A swollen neck

Alexander Woywodt, Saskia Merkel, Werner Buth, Hermann Haller, Anke Schwarz

An 18 year-old woman was transferred to our department in April, 2002, with a diagnosis of fever of unknown origin. She had previously been admitted to another hospital with spiking fever of a few days duration but evaluation there had failed to reach a diagnosis and she was given oral macrolides for presumed community-acquired pneumonia. Her fever had not resolved. On examination, she was feverish, acutely ill, and complained about pain and stiffness in her neck. On examination, her neck was stiff and the front of her neck swollen and tender. Her chest was clear and the remainder of the clinical examination showed no abnormalities. Laboratory studies showed leucocytosis, thrombocytopenia, and a C-reactive protein of 132 mg/L. A previously healthy grammar school student, she denied illicit drug use, had no history of travel, and was on no medication except for an oral contraceptive. Meningitis was suspected and cephtriaxone was begun. Lumbar puncture, however, showed clear cerebrospinal fluid without cells. Rigors persisted, she developed coagulopathy and during the late evening of the day of admission she became hypotensive despite intravenous fluids. Tobramycin was added to cephtriaxone and she was transferred to the intensive care unit with a diagnosis of septic shock of unknown aetiology.

Doppler ultrasound and computed tomography of the neck with contrast showed thrombosis of the internal jugular vein (figure). A diagnosis of Lemierre's syndrome was made and clindamycin was begun. A computed tomogram of her chest showed pulmonary infiltrates and bilateral pleural effusions but no intrapulmonary abscess. Ligation and excision of the left internal jugular vein were done one day after admission to intensive care after she had failed to improve on antibiotics. She was discharged after 5 days in intensive care and made an uneventful recovery. Blood cultures eventually grew *Fusobacterium nucleatum* and serology showed recent Epstein-Barr virus infection. When last seen in September, 2002, she was in good health.

Lemierre's syndrome is thrombophlebitis of the internal jugular vein due to anaerobic infection. A bacteriologist at Claude Bernard Hospital in Paris, Andre Lemierre (1875–1956) described 20 patients in 1936 in *The Lancet* although similar cases had been reported earlier. The disease usually affects young adults and incidence rates of one per million people a year have been reported.² Oral anaerobes, particularly *Fusobacterium* species, are the most frequently isolated and invasion is usually from intra-oral disease, such as bacterial tonsillitis, Epstein-Barr virus infection, or dental disease. Metastatic infection,



Computed tomography of the neck with radiocontrast showing thrombosis of the left internal jugular vein (arrow)

particularly pleuropulmonary, is common and a major cause of morbidity.³ Lesions of the carotid artery are less frequent.⁴ Once almost uniformly fatal, Lemierre's syndrome still carries a mortality rate as high as 20%. The diagnosis is suggested by fever, pain, and swelling along the angle of the jaw and sternocleidomastoid muscle. Occasionally, the thrombosed vein may be palpable. Computed tomography of the neck with contrast is the diagnostic procedure of choice. Antibiotic treatment must be with drugs active against anaerobes, such as clindamycin or the carbapenems.⁵ Anticoagulation is controversial because of the risk of disseminating infection. Surgery to ligate the internal jugular vein is occasionally required because of continuing sepsis, localised collections of pus, or embolism despite antibiotic treatment. Clinicians who are unaware of Lemierre's syndrome may easily underestimate the severity of this disease and employ standard antibiotic regimens, such as those for meningitis or pneumonia. Once seen, Lemierre's syndrome is unlikely to be forgotten.

References

- 1 Lemierre A. On certain septicaemias due to anaerobic organisms. *Lancet* 1936; **1**: 701–03.
- 2 Hagelskjaer LH, Prag J, Malczynski J, et al. Incidence and clinical epidemiology of necrobacillosis, including Lemierre's syndrome, in Denmark 1990–1995. *Eur J Clin Microbiol Infect Dis* 1998; **17**: 561–65.
- 3 Sinave CP, Hardy GK, Fardy PW. The Lemierre syndrome: suppurative thrombophlebitis of the internal jugular vein secondary to oropharyngeal infection. *Medicine* 1989; **68**: 85–94.
- 4 Maalikjy AN, Borroni B, Magoni M, et al. Lemierre's syndrome complicated by carotid thrombosis. *Neurol Sci* 2001; **22**: 403–04.
- 5 Hagelskjaer KL, Prag J. Human necrobacillosis, with emphasis on Lemierre's syndrome. *Clin Infect Dis* 2000; **31**: 524–32.

Lancet 2002; **360**: 1838

Division of Nephrology, Department of Medicine (A Woywodt MD, S Merkel MD, W Buth MD, H Haller MD, A Schwarz MD), Hannover Medical School, Hannover, Germany

Correspondence to: Dr Alexander Woywodt, Medical Intensive Care Unit, Department of Medicine, Hannover Medical School, Carl-Neuberg-Strasse-1, 30625 Hannover, Germany (e-mail: Woywodt.Alexander@MH-Hannover.de)