

# Cardiopulmonary Auscultation

## *Duo for Strings—Opus 99*

Alexander Woywodt, MD; Marion Höfer, MD; Bernhard Pilz, MD;  
Wolfgang Schneider, MD; Rainer Dietz, MD; Friedrich C. Luft, MD

**I**n spite of increasing mechanization in medicine and reliance on “high-tech” diagnostic tools, bedside clinical skills of the attending physician can still identify findings that are missed by the more sophisticated devices. Using a stethoscope, we relied on our skills in inspection, palpation, percussion, auscultation, as well as echocardiography and phonocardiography to diagnose a patient whose murmur was very reminiscent of the D-sharp pizzicato in the Cello Sonata in F, Opus 99, by Johannes Brahms. Initial echocardiography was not helpful. We suspected an anomalous chorda and confirmed this with phonocardiography and a second echocardiography. Although advances in cardiac imaging are extremely helpful, the use of simple clinical skills, in addition to being fun, is not obsolete. Cardiopulmonary auscultation should receive more emphasis in the medical school curriculum and clinical training.

*Arch Intern Med.* 1999;159:2477-2479

The stethoscope has served as an important diagnostic tool in cardiovascular evaluation since its introduction by Laënnec in 1816.<sup>1</sup> However, with the advent of numerous new diagnostic modalities such as echocardiography and magnetic resonance imaging, cardiopulmonary auscultation is receiving less emphasis in both teaching and practice.<sup>2</sup> Phonocardiography, the graphic recording of heart sounds that served as a means of teaching and documenting auscultation, has largely disappeared. Among both medical students and practicing physicians, the belief that auscultatory skills are of secondary importance appears to be widespread. For example, the cardiac auscultatory skills of internal medicine and family practice residents were recently examined in a multicenter, cross-sectional assessment.<sup>3</sup> The residents were able to recognize only 20% of cardiac events. More disturbingly, their skills failed to improve with years of additional training and differed only slightly from those of beginning medical students. However, our clinical team recently encountered a patient whose cardiac sounds presented an interesting auscultatory challenge for us, and

allowed us the enjoyment and satisfaction of being the masters of “high tech” instrumentation.

### REPORT OF A CASE

A 51-year-old man with a long history of dilated cardiomyopathy and heavy alcohol consumption was admitted for shortness of breath and progressive abdominal distention. In his medical record, no mention of abnormal or unusual heart sounds had been made.

### *For editorial comment see page 2396*

Physical examination disclosed a blood pressure of 110/68 mm Hg, irregular pulse of 90/min, and respiratory rate of 20/min. The jugular veins were distended with the patient sitting, and a variable but prominent V wave was visible. The apex beat was visible in the anterior axillary line, and the cardiac motion was palpable at the sternum. The pulmonic closure of the second heart sound was particularly prominent, and a third heart sound was audible at the apex. The first heart sound varied in intensity and was followed by an unusual variable: a musical systolic murmur along the left and right lower sternal border, which continued

*From the Franz Volhard Clinic (Drs Woywodt, Höfer, Pilz, Dietz, and Luft); and Department of Pathology, Klinikum Buch Hospital, Medical Faculty of the Charité, Humboldt University of Berlin (Dr Schneider), Berlin, Germany*

through both components of the second heart sound. The murmur increased in intensity with inspiration and decreased while sitting. The murmur increased when the legs were raised from the bed, but failed to increase by gripping firmly with the hands. The murmur had a quality that can best be described as a loud “DOINGGG.” Palpation with the flat palmar surface disclosed a vibratory sensation. One observer commented that the murmur closely resembled the D-sharp pizzicato for violoncello in the Adagio affettuoso of Johannes Brahms’ Cello Sonata in F, Opus 99 (Figure, A). An experienced auscultator suggested that the sound may be the result of an anomalous chorda extending across the right ventricular cavity. Abdominal examination disclosed an enlarged pulsatile liver, hepatojugular reflux, and ascites. Peripheral edema was also identified.

A chest roentgenogram disclosed cardiomegaly. Electrocardiogram confirmed atrial fibrillation.

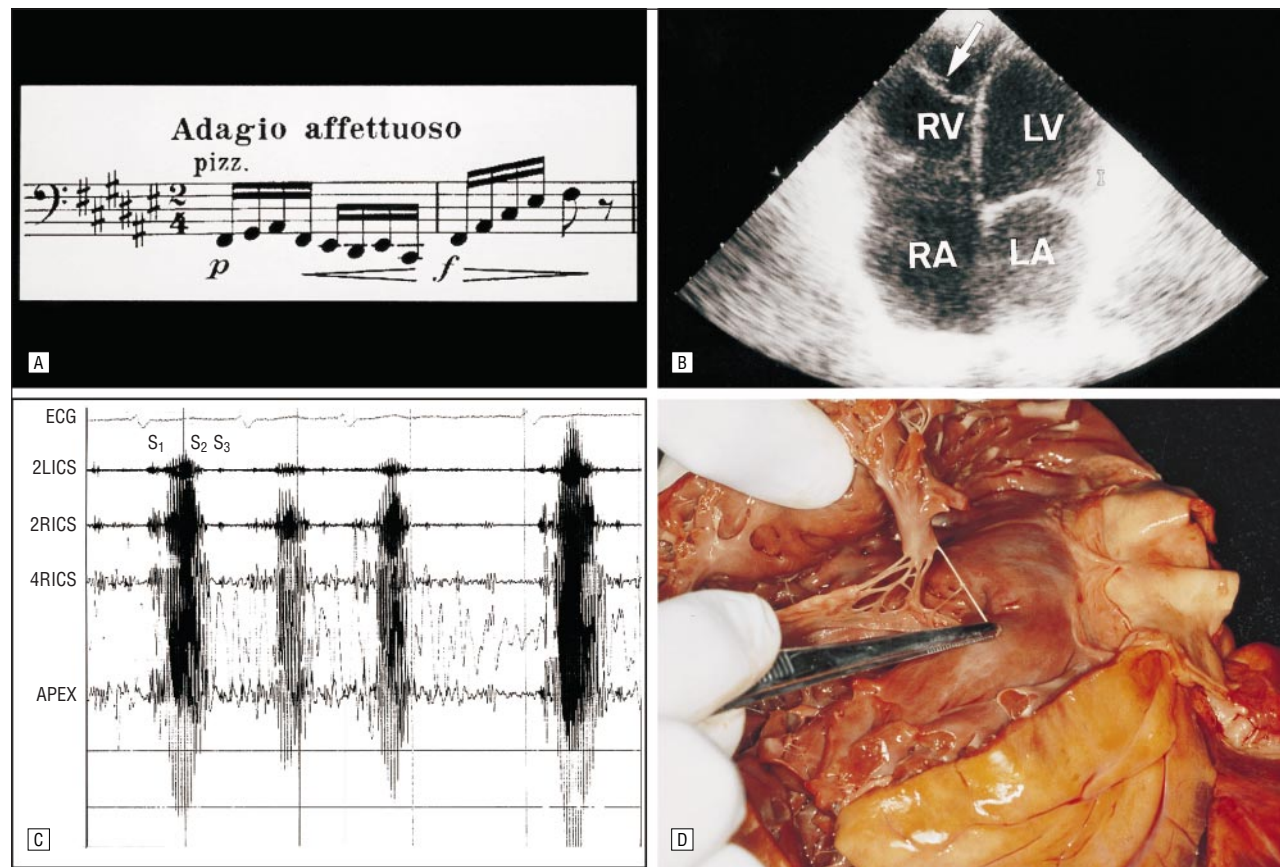
The QRS complex was small and narrow with right axis deviation. An initial echocardiogram revealed tricuspid regurgitation, as suggested by the physical examination; however, no anomalous chorda was observed. A second echocardiographic examination was requested, which revealed an anomalous chorda within the right ventricle (Figure, B). With considerable effort, we discovered a vacuum tube-operated phonocardiogram in the basement of the pediatrics department. This venerable piece of equipment generated a tracing (Figure C). The patient was treated with furosemide and metolazone and improved sufficiently to leave the hospital. Unfortunately, he reappeared 3 months later with worsening symptoms and a further increase in heart size. Interestingly, the murmur was now only barely audible. He died in his sleep on the fourth hospital day. Postmortem examination showed advanced dilated cardiomyopathy, mild focal endocardial fibroelastosis, a small papillary fibroelastoma of the aortic valve (not

shown), and 2 anomalous chordae—1 in the right ventricle (Figure, D) and 1 in the left ventricle (not shown).

#### COMMENT

Our patient presented an auscultatory diagnostic challenge as well as a focal point for teaching the skills and joys of cardiopulmonary auscultation. He was an exceptionally cooperative patient who allowed medical students, hospital staff, and faculty physicians to repetitively examine him and discuss, at his bedside, the diagnostic techniques and fine points of the cardiac examination. His compliance underscores the debt that is owed to those patients who are willing to serve as teachers by making themselves available to strangers for the purpose of furthering medical knowledge and experience.

Systolic murmurs continue to present a challenge to clinicians. Lembo et al<sup>4</sup> found that, although no single maneuver is 100% accurate in diagnosing the cause of a systolic



A, Opening measures to the Adagio affettuoso of Johannes Brahms’ Cello Sonata in F, Opus 99 (Münch-Holland edition, Henle Verlag, Munich, 1949). B, Echocardiogram, with arrow indicating an anomalous chorda within the right ventricle (RV). C, Phonocardiogram showing electrocardiogram (ECG) and recordings at left and right intercostal spaces (LICS and RICS, respectively) and apex. D, Anomalous chorda at autopsy.

murmur, a murmur's origin can be determined accurately in most cases by simple bedside maneuvers. In their study, augmentation with inspiration had 100% sensitivity, with 88% specificity for right-sided murmurs. We recognized the presence of tricuspid regurgitation because of the prominent V waves in the jugular pulse that appeared with each heart beat. Laënnec himself commented on diagnosing right-sided heart disease:

With regard to the swollen state of the jugulars which M. Corvisart considers of little importance, I am disposed to look upon it as the most constant and characteristic of the equivocal signs of this affliction. The only constant and truly pathognomonic symptom, however, is the loud sound of the heart perceived at the bottom of the sternum, and between the cartilages of the fifth and seventh ribs of the right side.<sup>1(p345)</sup>

The D-sharp pizzicato suggested an anomalous chorda, although similar systolic sounds can be heard with venous hums or the bruit de Roger. Interestingly, a discussion of anomalous chordae is not included in recently published "high tech" cardiology textbooks.<sup>5</sup> However, Friedberg<sup>6</sup> provides a brief but elucidative description of the structures and auscultatory findings and their clinical significance. There are no recent reports on this condition in the English-language literature.<sup>7</sup> Echocardiography is useful in diagnosing anomalous chordae in living patients, although, as our patient illustrates, examiners are greatly helped when clinicians provide detailed auscultatory information and guide them toward the findings that should be sought.

Tavel<sup>8</sup> pointed out that the examiner should first attempt to decide whether a given murmur continues to the second heart sound, and that a murmur may be classified as regurgitant if it encompasses both components of this sound. The blowing (high pitch) murmur with maximum intensity at the lower-left sternal border was coupled with the vibratory pizzicato accentuation, which we interpreted as a combination of tricuspid regurgitation and the hum of an anomalous chorda. We speculate that, without the regurgitant gradient provided by tricuspid regurgitation, the chorda would have made no noise. The fact that the pizzicato was almost gone at the second admission, when the cardiac function was much worse, suggests an insufficient gradient between the right ventricle and atrium to generate the noise.

Our patient underscores the glorious past enjoyed by cardiopulmonary auscultation. In earlier times, the clinical examination was all that physicians had available to diagnose heart disease, and the physician's skill was measured by how well cardiopulmonary auscultation was conducted. Tavel has suggested that new developments to capture heart sounds and murmurs are warranted.<sup>9</sup> He suggested advanced stethoscopes with noise rejection, improved visual display of sound data, and graphic representation of cardiovascular sounds. Although several electronic stethoscopes are available,<sup>10</sup> it remains to be demonstrated that these devices substantially improve cardiopulmonary auscultation. Until then, the trusty old fashioned hearing piece,

which has become the trademark of the physician, should be put to a more practical use than merely a cervical decoration.

Accepted for publication April 15, 1999.

We thank our teachers, who took the time to impart a portion of their skills and enthusiasm for the cardiac examination.

Reprints: Friedrich C. Luft, MD, Franz Volhard Clinic, Wiltberg Strasse 50, 13122 Berlin, Germany (e-mail: luft@fvk-berlin.de).

## REFERENCES

1. Willis FA, Keys TE, eds. Rene Theophile Hyacinthe Laënnec. In: *Classics of Cardiology*. New York, NY: Dover Publications Inc; 1961: 323-384.
2. Mangione S, Nieman LZ, Gracely E, Kaye D. The teaching and practice of cardiac auscultation during internal medicine and cardiology training. *Ann Intern Med*. 1993;119:47-54.
3. Mangione S, Nieman LZ. Cardiac auscultatory skills of internal medicine and family practice trainees. *JAMA*. 1997;278:717-722.
4. Lembo NJ, Dell'Italia LJ, Crawford MH, O'Rourke RA. Bedside diagnosis of systolic murmurs. *N Engl J Med*. 1988;318:1572-1578.
5. Braunwald E. *Heart Disease*. 5th ed. Philadelphia, Pa: WB Saunders; 1997.
6. Friedberg CK. Congenital heart disease. In: *Diseases of the Heart*. Philadelphia, Pa: WB Saunders. 1966;85:1298.
7. Lurenev AP, Devereaux R, Rynskova EE, Dubov PB. Ob anomalnykh khordakh serdtsa (Anomalous chordae tendineae). *Ter Arkh*. 1995;67: 23-25.
8. Tavel ME. Classification of systolic murmurs: still in search of a consensus. *Am Heart J*. 1997;134: 330-336.
9. Tavel ME. Cardiac auscultation: a glorious past-but does it have a future? *Circulation*. 1996;93: 1250-1253.
10. Grenier MC, Gagnon K, Genest J Jr, Durand J, Durand LG. Clinical comparison of acoustic and electronic stethoscopes and design of a new electronic stethoscope. *Am J Cardiol*. 1998;81: 653-656.